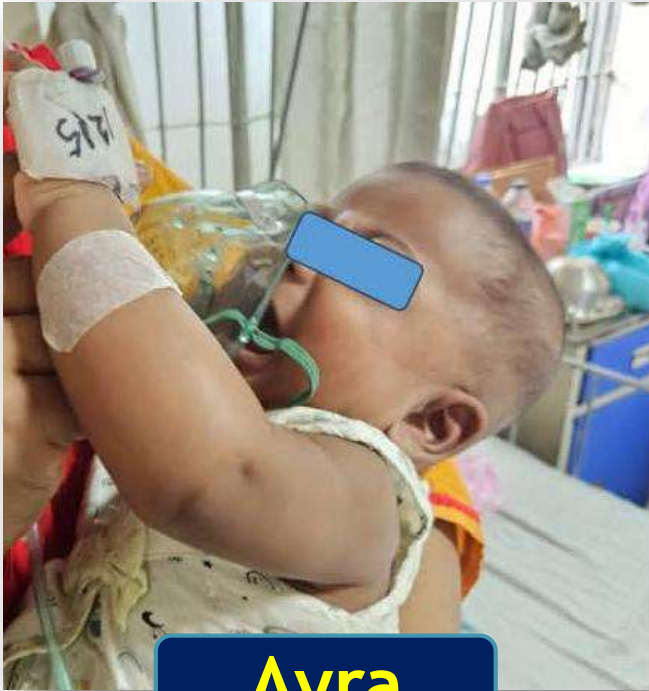

Endoscopic Removal of Toy Switch



Case scenario

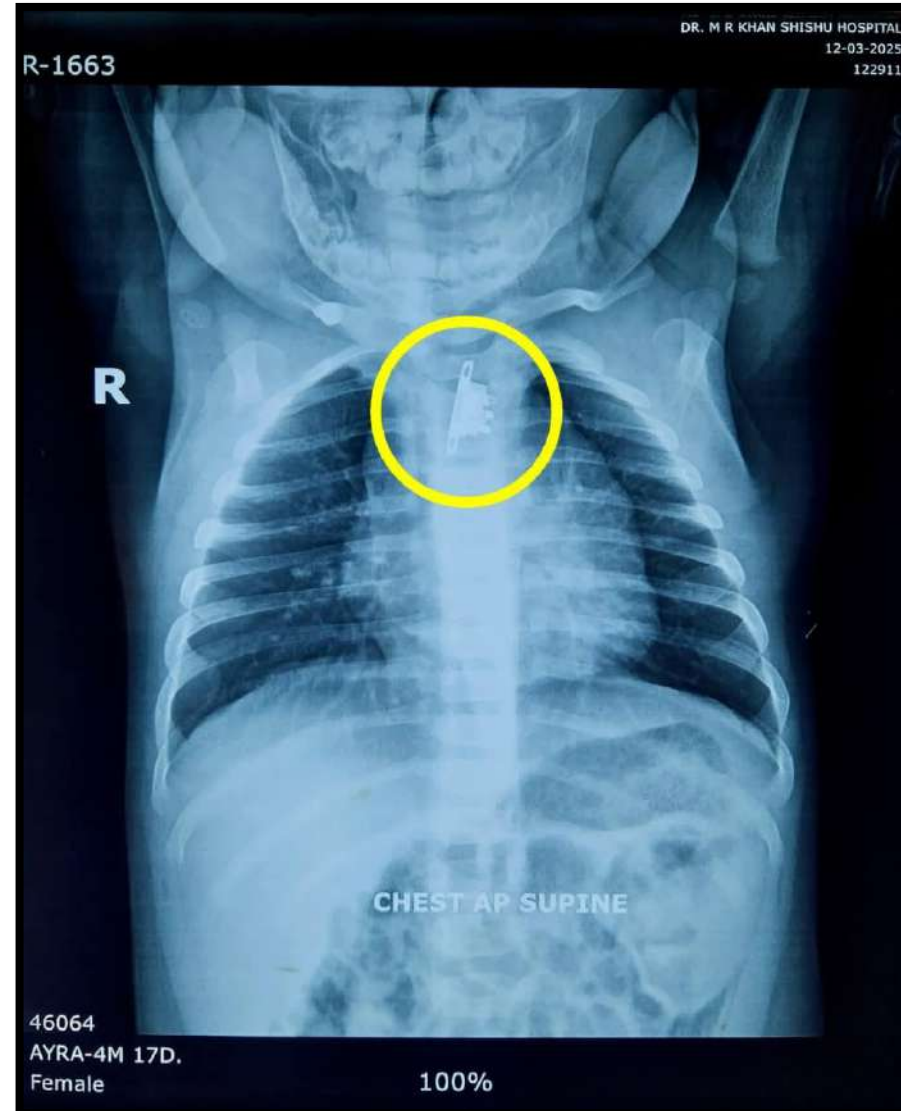


Ayra

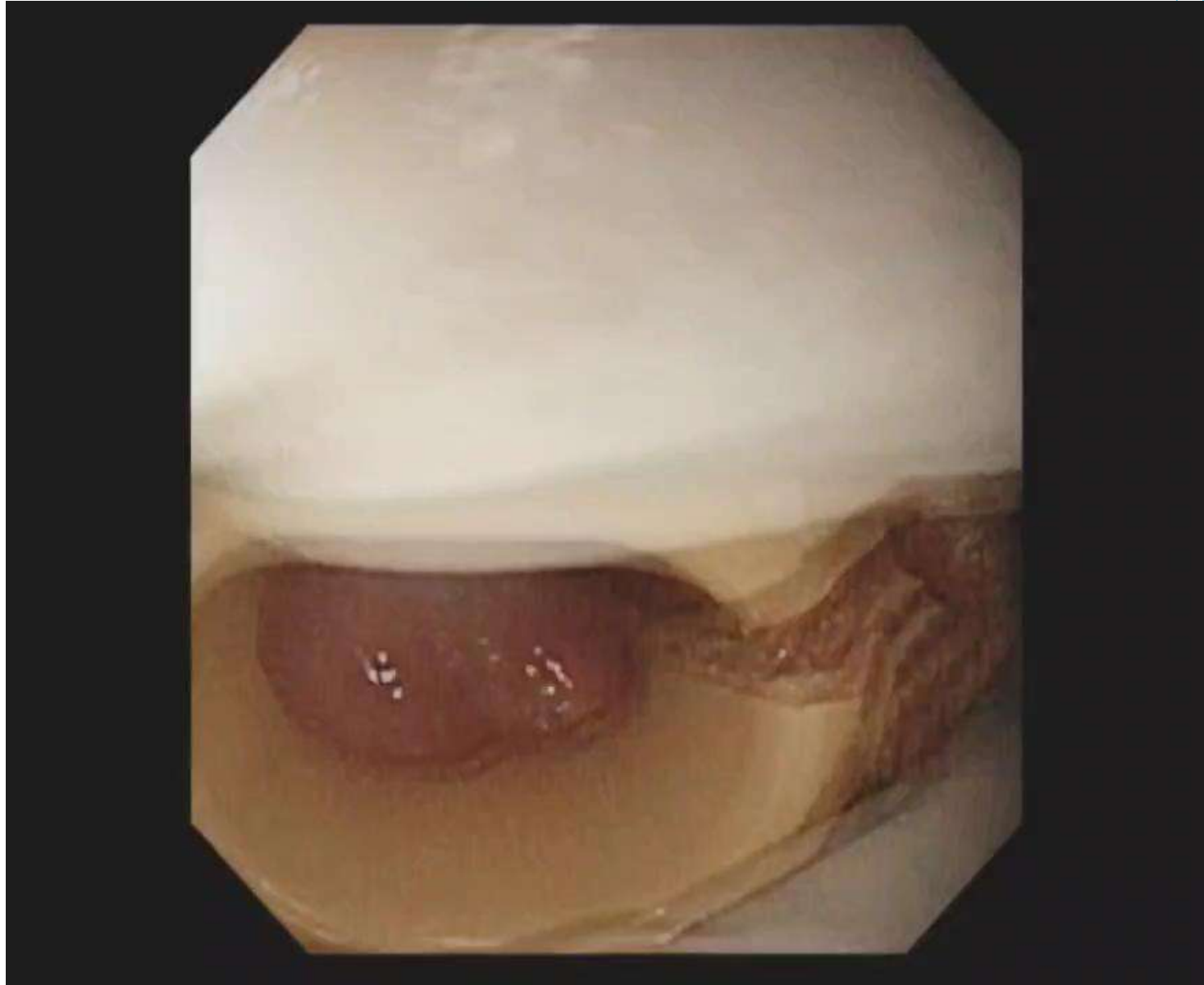
□ A **4 months** old neonate, only **6 kg**, was presented with the complaints of:

□ Accidental ingestion of **toy switch** which was introduced by his own brother of 4 years







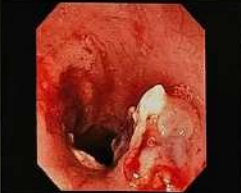
We performed an **X-ray** on an
emergency basis

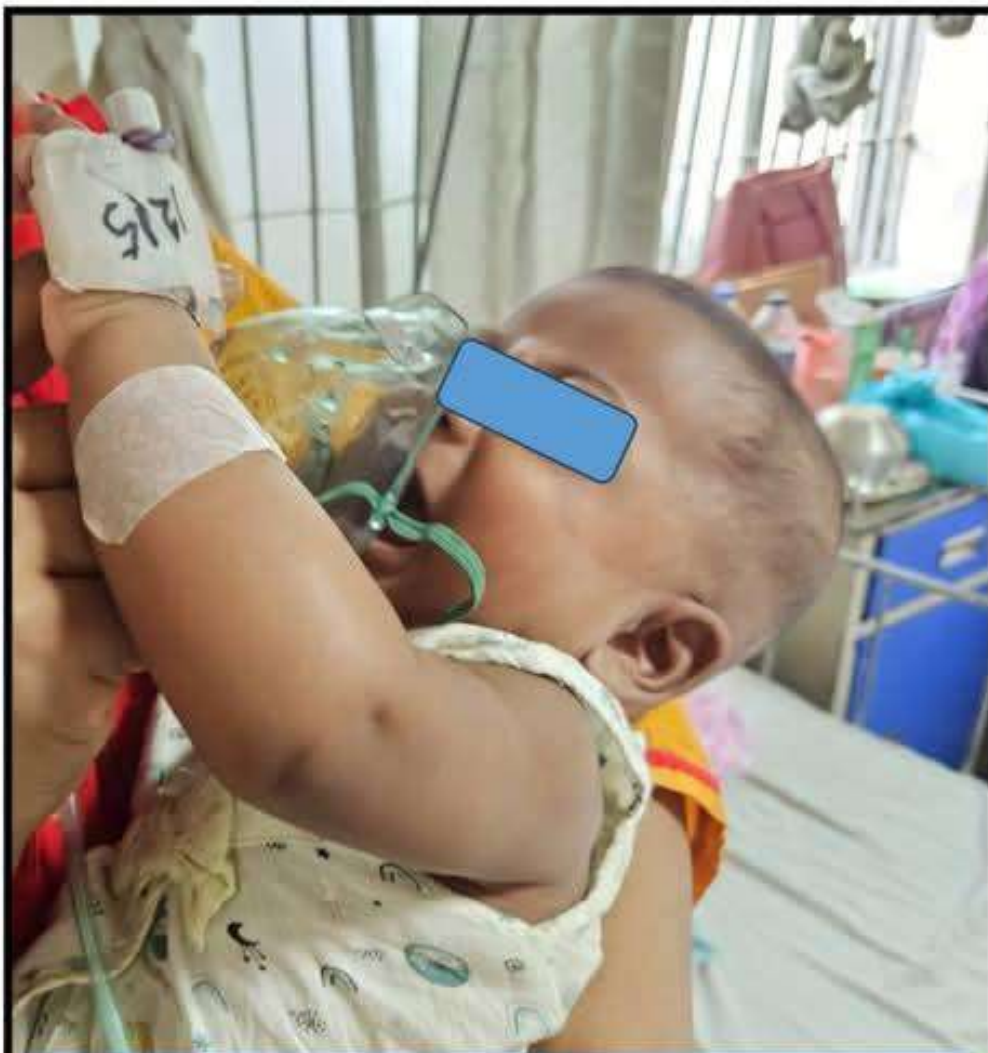

Endoscopy Video

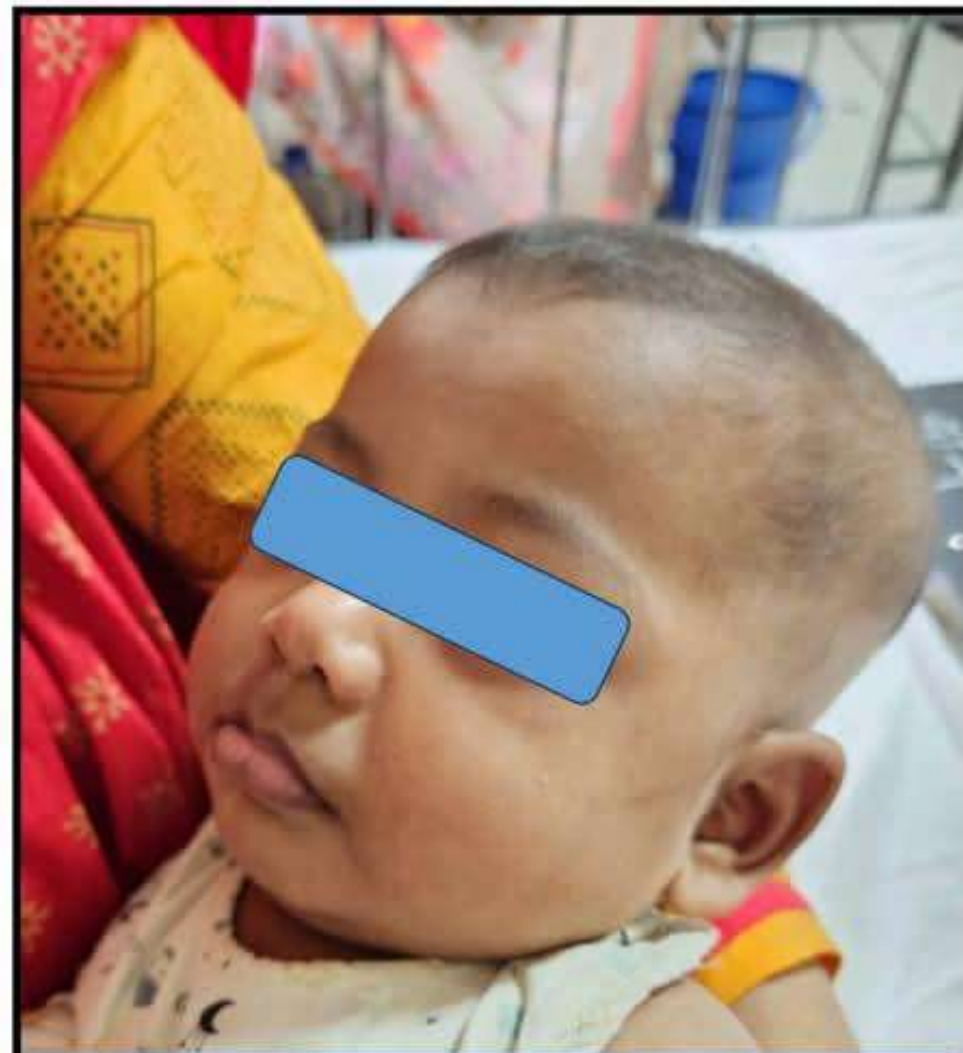

Endoscopy Report

BANGLADESH SHISHU HOSPITAL & INSTITUTE Sher-e-bangla Nagar, Dhaka-1207			
Identity No.	00001800	Visit Date	13 March, 2025
Patient Name	Ayra	Age / Sex	0.4 / Female
History	Foreign Body Ingestion	Instrument	Olympus CV-190
Referrer	OPD	Bed	OPD
ENDOSCOPIC PROCEDURE REPORT			
 Esophagus (upper end)			
 Foreign body at middle part of esophagus			
 During intervention			
Procedure : UPPER GI Endoscopy			
Indication : Foreign body ingestion			
Medication : Inj. Midazolam IV Slowly			
FINDINGS:			
• Esophagus: A foreign body (toy switch) was found stuck in the middle part of esophagus. Deep ulceration & mucosal inflammation was seen at that region. During intervention it was removed by using rat tooth forcep.			
• Stomach: Normal findings			
• Duodenum: Not seen.			
COMMENTS: Endoscopic removal of the foreign body (toy switch).			
 Prof. Dr. Salahuddin Mahmud MBBS, MD (Pediatrics) Fellow training in Ped. Endoscopy Apollo Hospital, New Delhi (India) Sheffield Children Hospital (UK) Professor Pediatric Gastroenterology Hepatology & Nutrition		Prof. Dr. Syed Shafi Ahmed DCH, MD, FRCP, PhD Fellow training in Ped. Endoscopy Apollo Hospital, New Delhi (India) Sheffield Children Hospital (UK) Professor & Head Pediatric Gastroenterology, Hepatology & Nutrition	
 After removal			
 After removal			
 Deep ulceration at middle part of esophagus			
Developed by: T. H. RIYAD www.bissoft.net Distributed by: AL-FATAH INTERNATIONAL Phone: +880-2-9676101 Fax: +880-2-9676381 Email: info@al-fatah-bd.com			



Before Endoscopy



After Endoscopy

After Removal of Toy Switch



Ped Gastro Team

