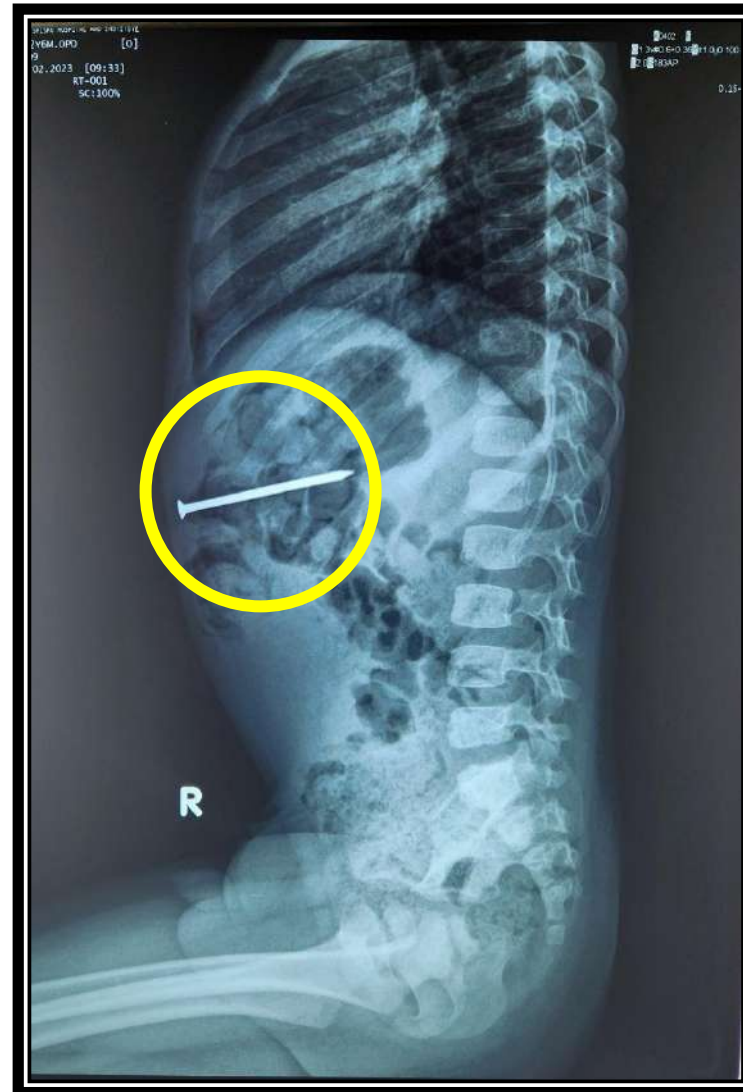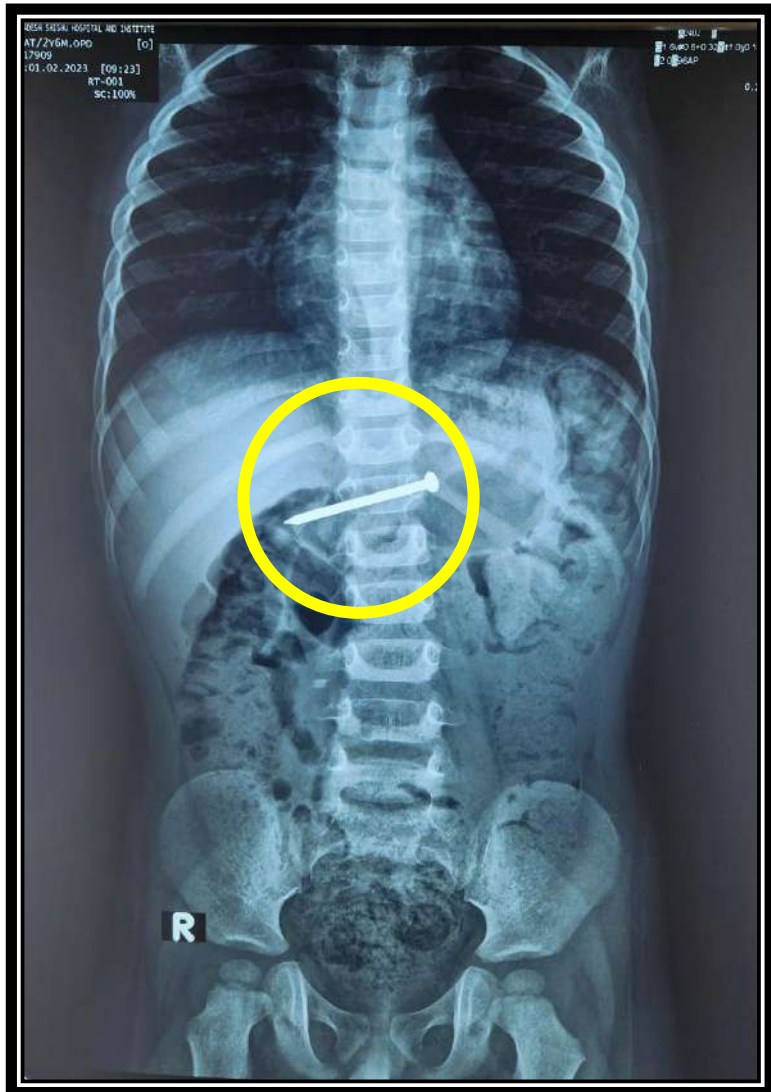



Endoscopic Removal of Iron Nail




Day-16






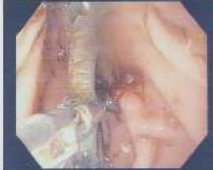


Endoscopy Video



Iron Nail after Removal



Endoscopy Report

BANGLADESH SHISHU HOSPITAL & INSTITUTE Sher-e-bangla Nagar, Dhaka-1207			
Identity No.	00001026	Visit Date	01 February, 2023
Patient Name	Sifat	Age / Sex	2.6 / Male
History	Accidental ingestion of Iron nail (Perek)	Instrument	CLV- 190
Referrer	OPD	Bed	OPD
ENDOSCOPIC PROCEDURE REPORT			
  			
Esophagus (Lower End) Stomach (Body) A Iron Nail in Body			
Procedure : UPPER G. I. TRACT ENDOSCOPY			
Indication : Accidental ingestion of Iron nail (Perek)			
Medication : Inj. Midazolam / IV Slowly with Dilution			
FINDINGS:			
• Oesophagus: The mucosa, vascular pattern, lumen and peristalsis appear normal. Upper & Lower oesophageal sphincters are normal in position and function.			
• Stomach: The mucosa of the fundus, body and antrum having multiple bleeding spots which was black in color. A six inch long iron nail (Perek) was found in the body of stomach.			
• Duodenum: The bulb, post-bulbar area and second part appear normal.			
COMMENTS: Endoscopic removal of iron nail (Perek) successfully			
Dr. Salahuddin Mahmud MRPS, MD (Pediatrics) Fellow training in Ped. Endoscopy Apollo Hospital, New Delhi (India) Sheffield Children Hospital (UK) Associate Professor Pediatric Gastroenterology Hepatology & Nutrition		Prof. Syed Shafi Ahmed DCH, MD, FRCP, PhD Fellow training in Ped. Endoscopy Apollo Hospital, New Delhi (India) Sheffield Children Hospital (UK) Professor & Head Pediatric Gastroenterology, Hepatology & Nutrition	
  			
Grasping with Rat tooth forcep During withdraw of iron nail After withdrawal			
Developed by: T. H. HIRAO www.hiroa.net Distributed by: AL-FAYAH INTERNATIONAL Phone: +965-26760091 Fax: +965-26760091 Email: info@al-fayah.com			