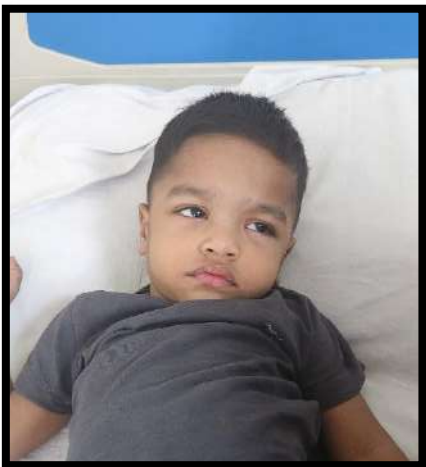

Endoscopic Removal of Hijab Pin



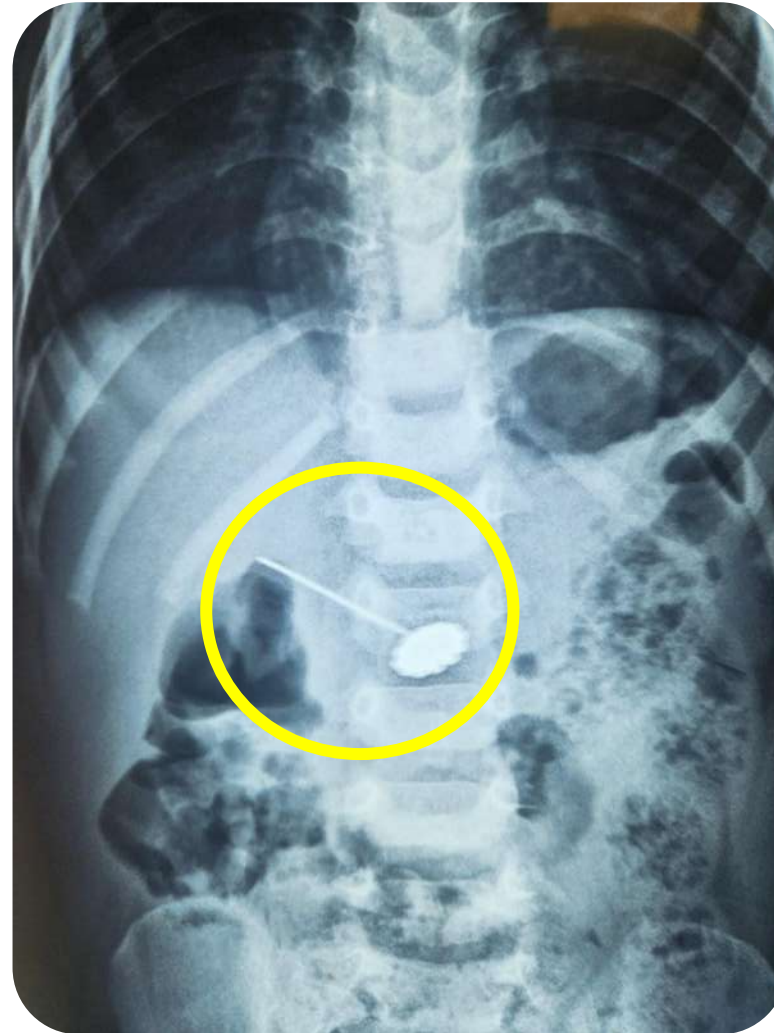
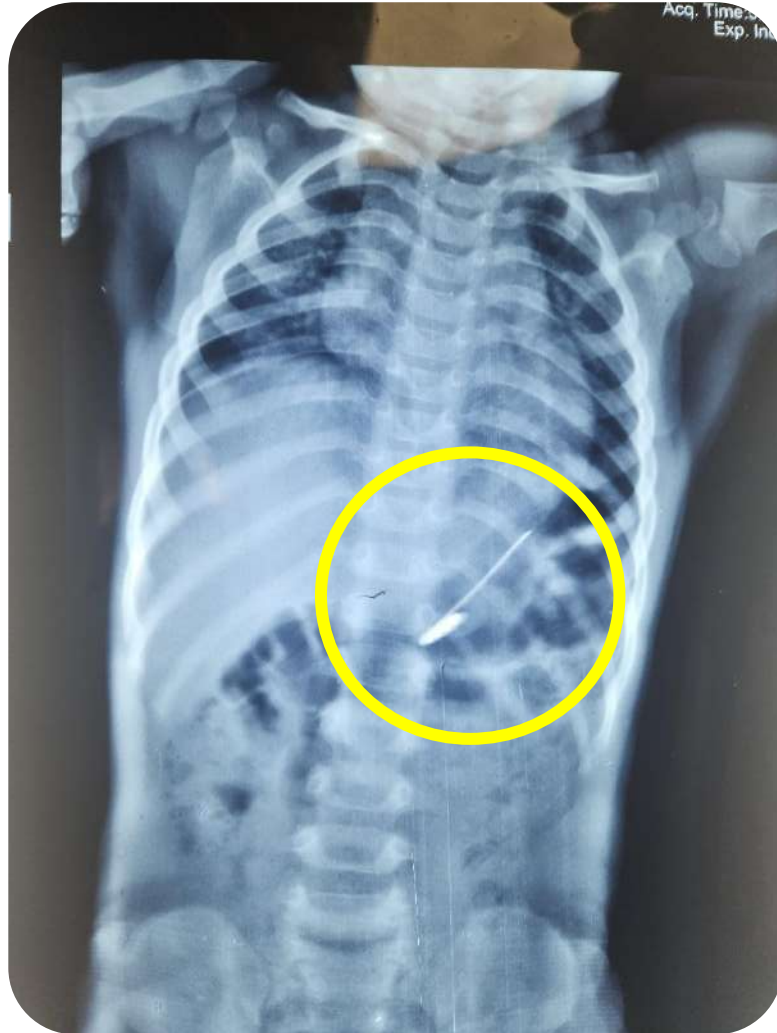Case scenario



Junayed



X-ray of Hijab Pin



International Recommendation

❑ If foreign body having **sharp end** and **>5 cm** then:

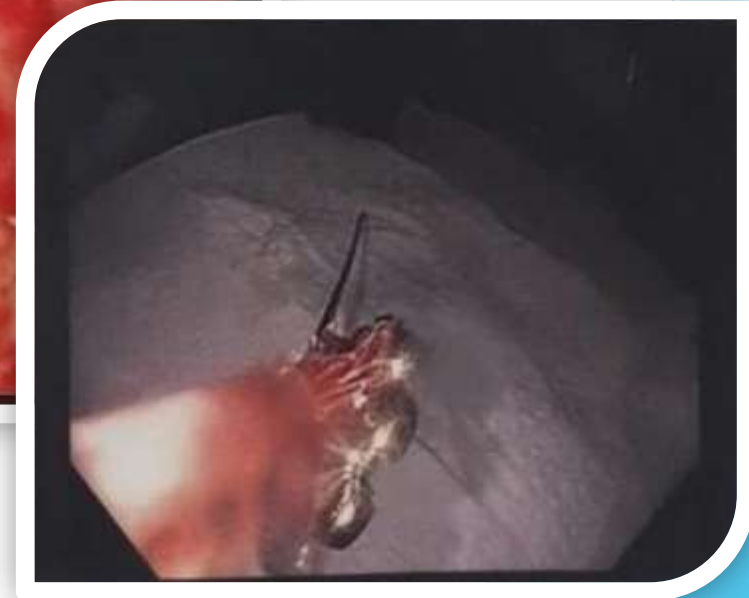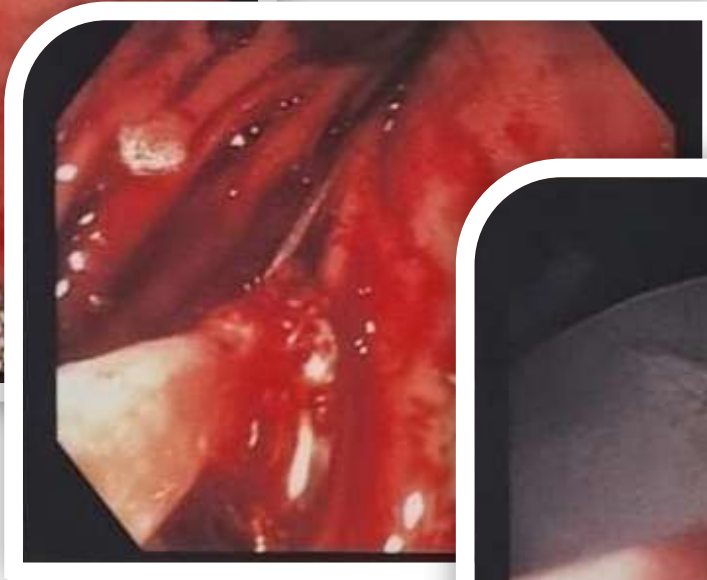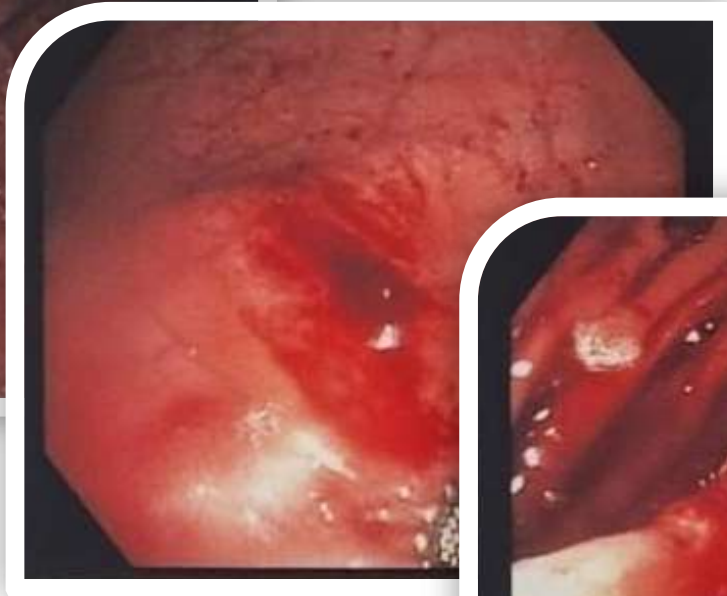
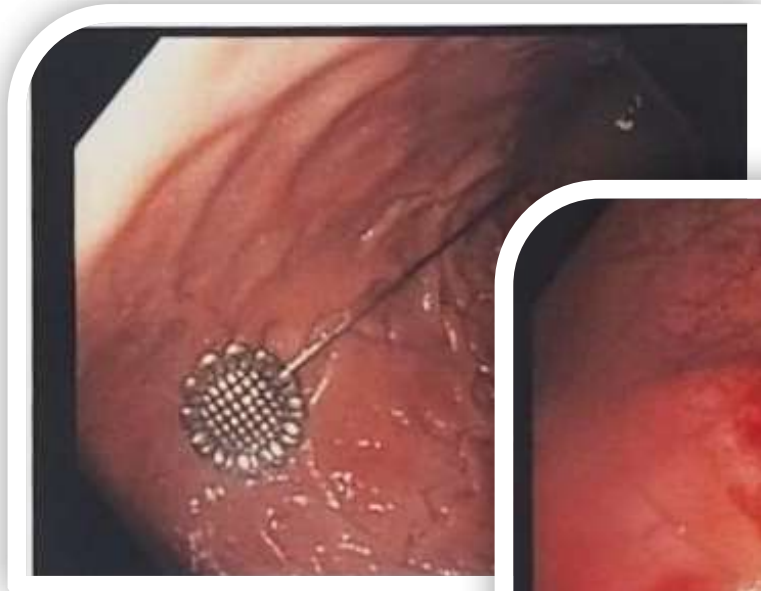❑ **Urgent removal** of
foreign body



Instruments for Endoscopic removal

Foreign body Roth Net




Endoscopic Images





Endoscopy Video

Length of Hijab Pin



**Before
Removal**



**After
Removal**



Paed Gastro Team





Thanks

The word "Thanks" is written in a stylized, cursive font. The letters are primarily blue with a yellow outline. A small butterfly is perched on the letter 'T', and another butterfly is flying above the letter 'h'.

Rely on us

Thank You All &

