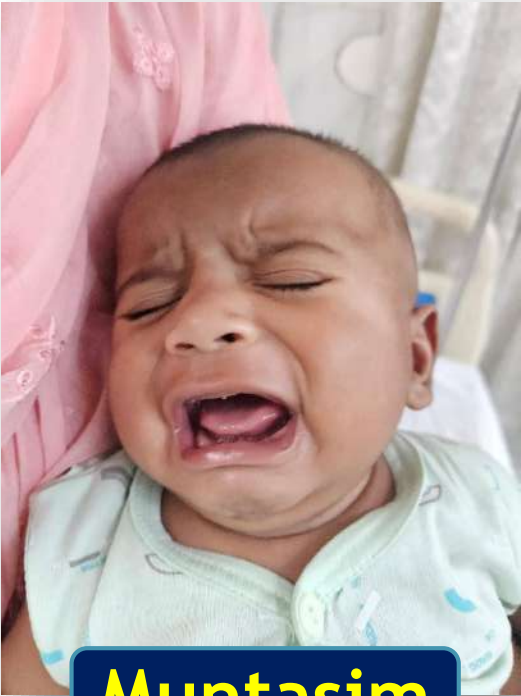

Endoscopic Removal of Ear Ring




Case scenario

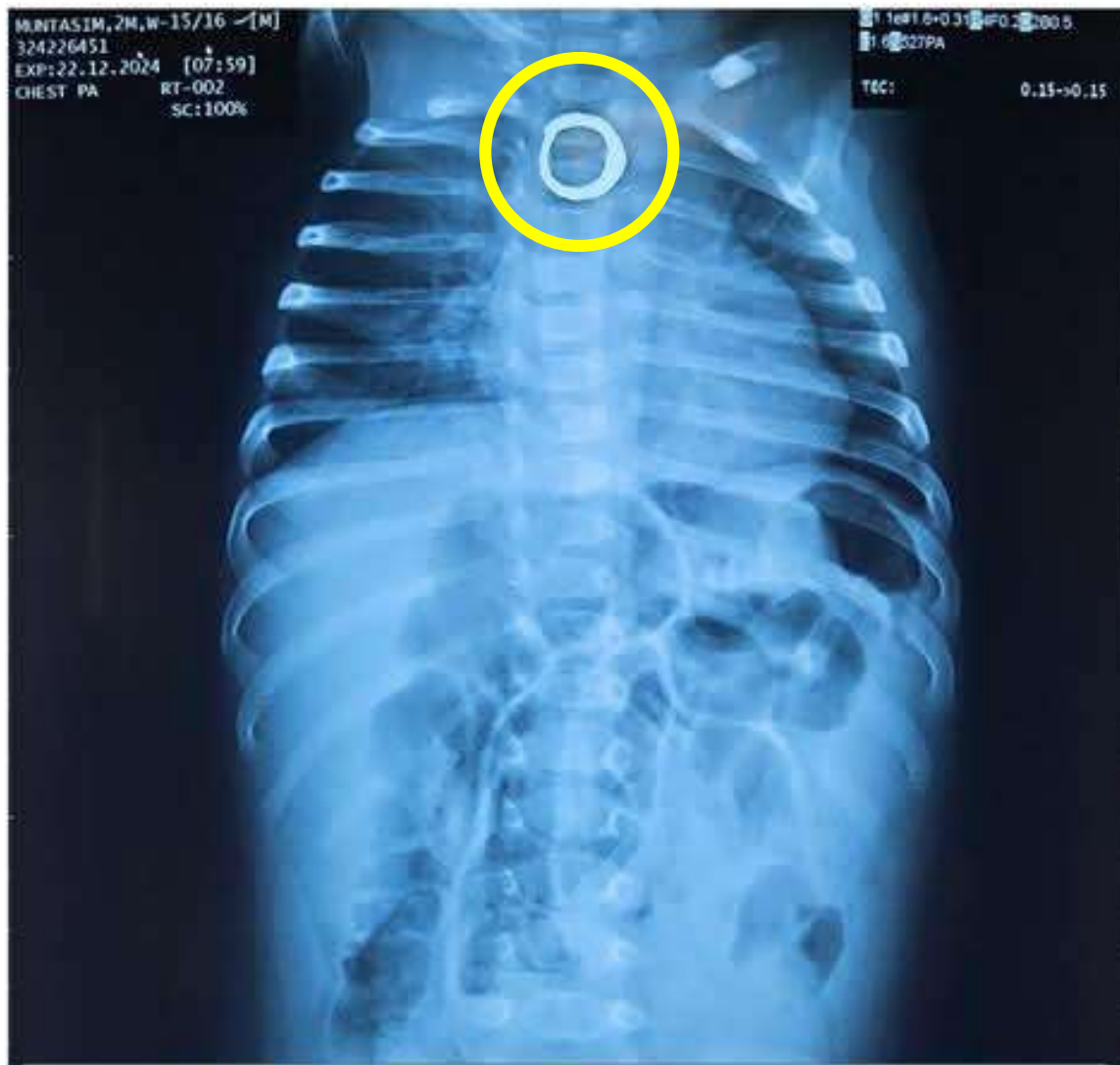


Muntasim

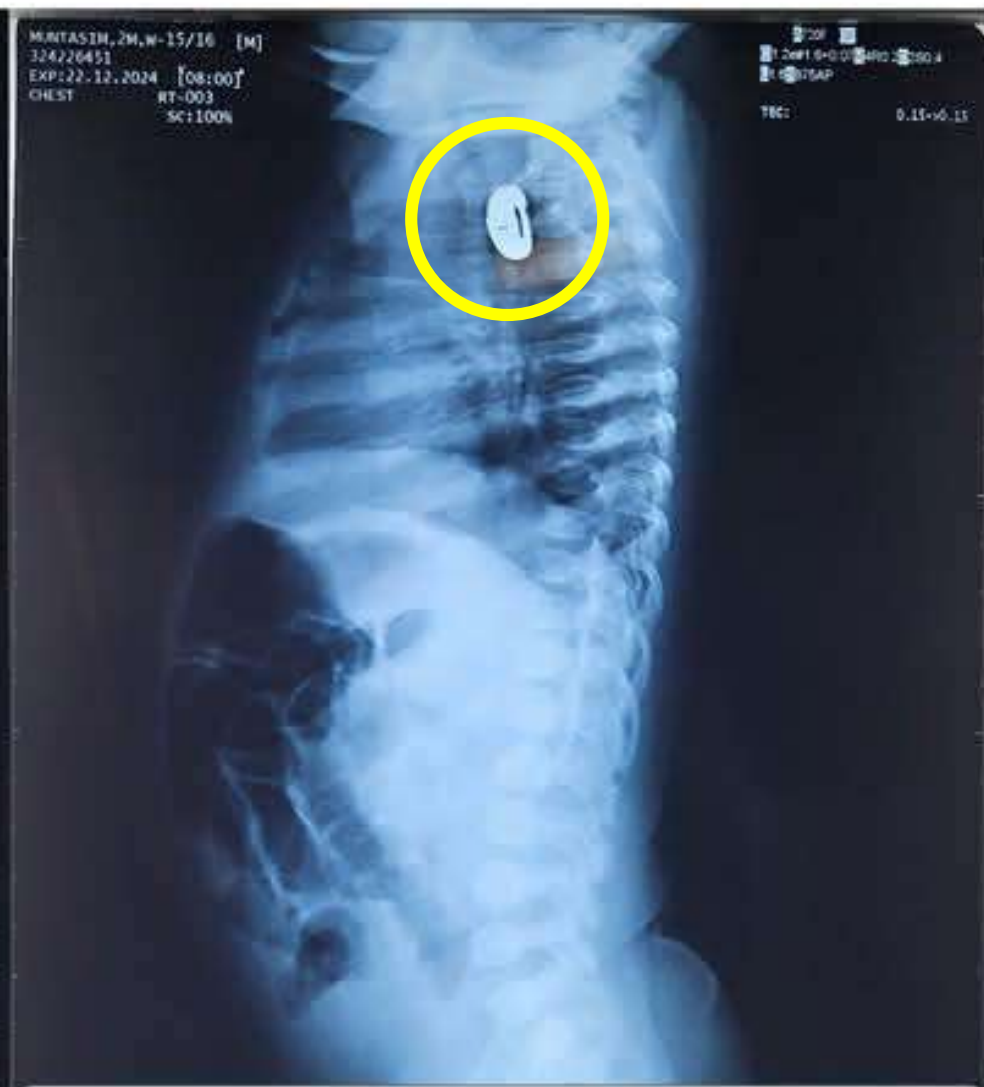- ❑ A **3 years**, only **12 kg**, was presented with the complaints of:



- ❑ Accidental ingestion of **Ear ring**



PA view



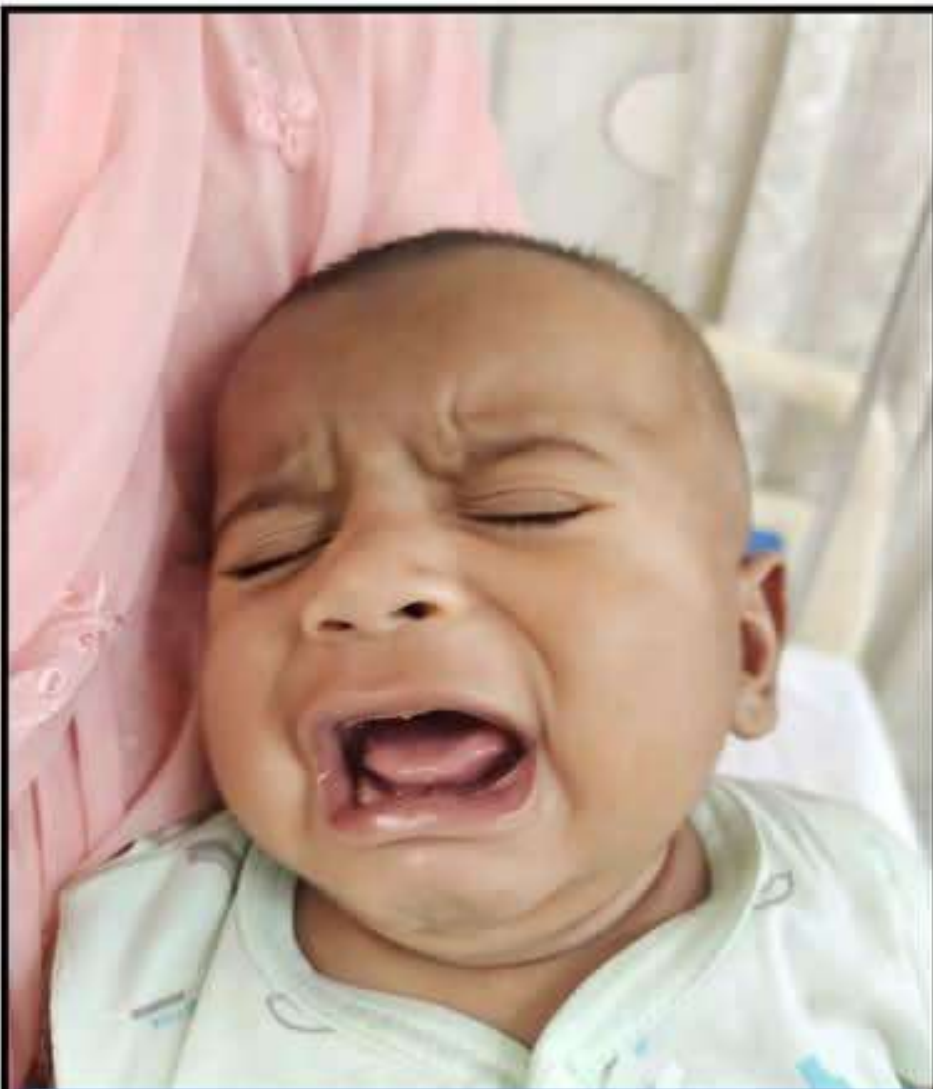Lateral view

Endoscopy Video

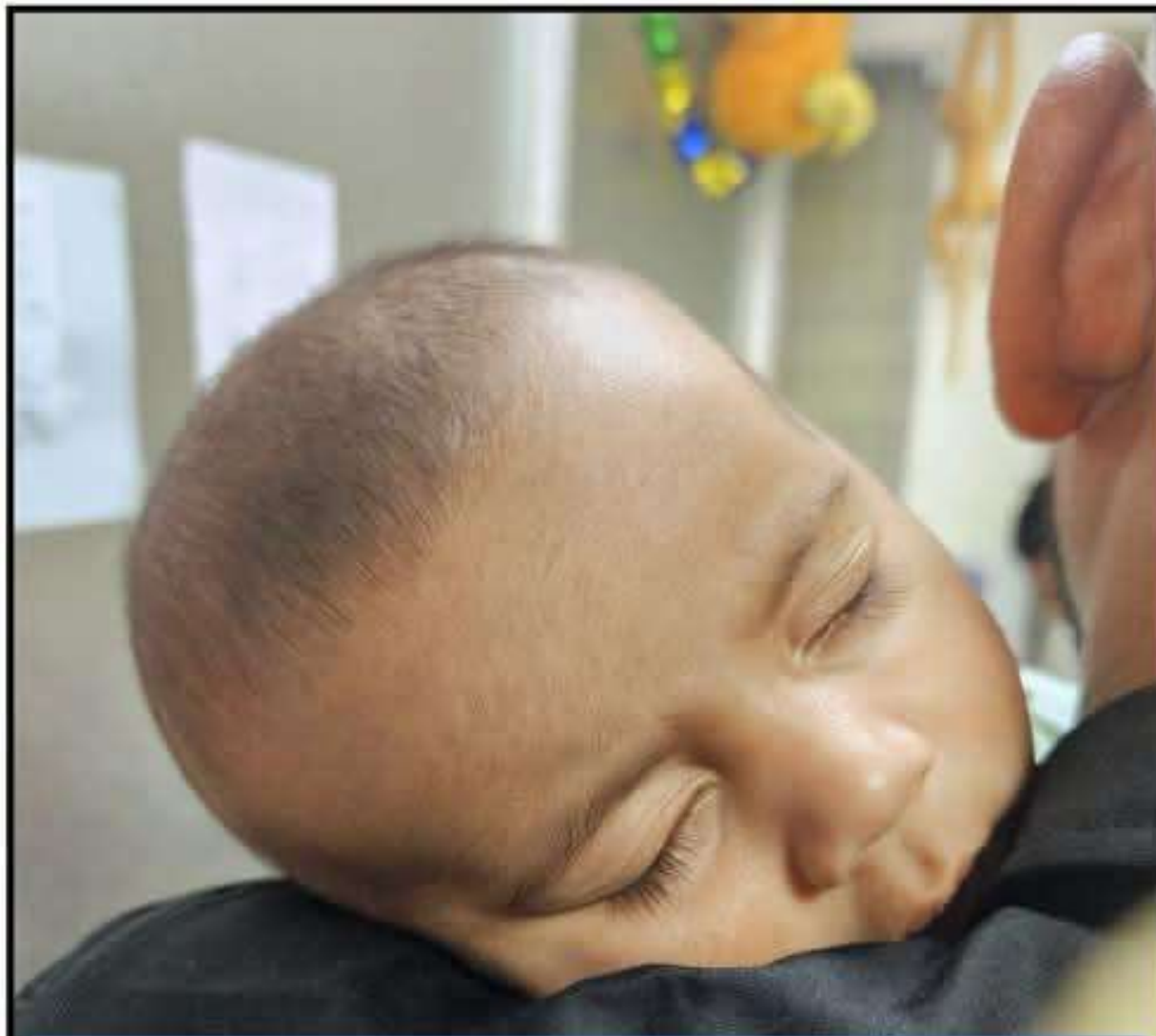

After Endoscopic Removal





Before removal



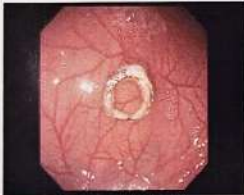


After removal

Endoscopy Report

BANGLADESH SHISHU HOSPITAL & INSTITUTE Sher-e-bangla Nagar, Dhaka-1207			
Identity No.	00001708	Visit Date	22 December, 2024
Patient Name	Muntasim	Age / Sex	3 / Male
History	Foreign Body Ingestion	Instrument	Olympus CV-190
Referrer	Prof. Syed Shafi Ahmed	Bed	W-15, B-16

ENDOSCOPIC PROCEDURE REPORT



Foreign body in stomach Foreign body in stomach Foreign body in stomach

Procedure : UPPER G. I. TRACT ENDOSCOPY


Indication : Foreign Body Ingestion

Medication : Inj. Midazolam IV Slowly

FINDINGS:




- **Oesophagus:**
The mucosa, vascular pattern, lumen and peristalsis appeared normal. Upper & Lower oesophageal sphincters were normal in position and function.
- **Stomach:**
There was a foreign body, metallic earring noted on the body of the stomach. It was removed successfully by foreign body Roth net.
- **Duodenum:** Not seen.

COMMENTS: Endoscopic removal of the foreign body (metallic earring)



Prof. Salahuddin Mahmud
MBBS, MD (Pediatrics)
Fellow training in Ped. Endoscopy
Apollo Hospital, New Delhi (India)
Sheffield Children Hospital (UK)
Professor
Pediatric Gastroenterology,
Hepatology & Nutrition

Prof. Syed Shafi Ahmed
DCH, MD, FRCP, PhD
Fellow training in Ped. Endoscopy
Apollo Hospital, New Delhi (India)
Sheffield Children Hospital (UK)
Professor & Head
Pediatric Gastroenterology,
Hepatology & Nutrition



During removal During removal After removal

Ped Gastro Team

