

# Endoscopic Removal of Clothes Clip Spring




# Case scenario

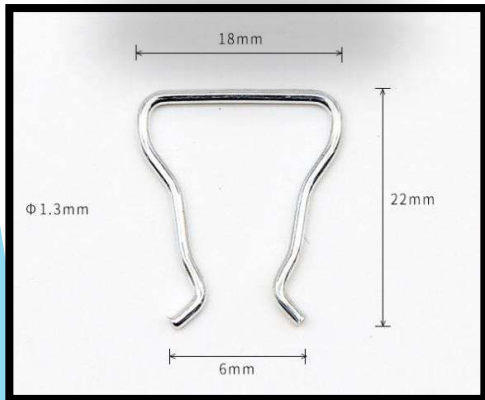


Manha

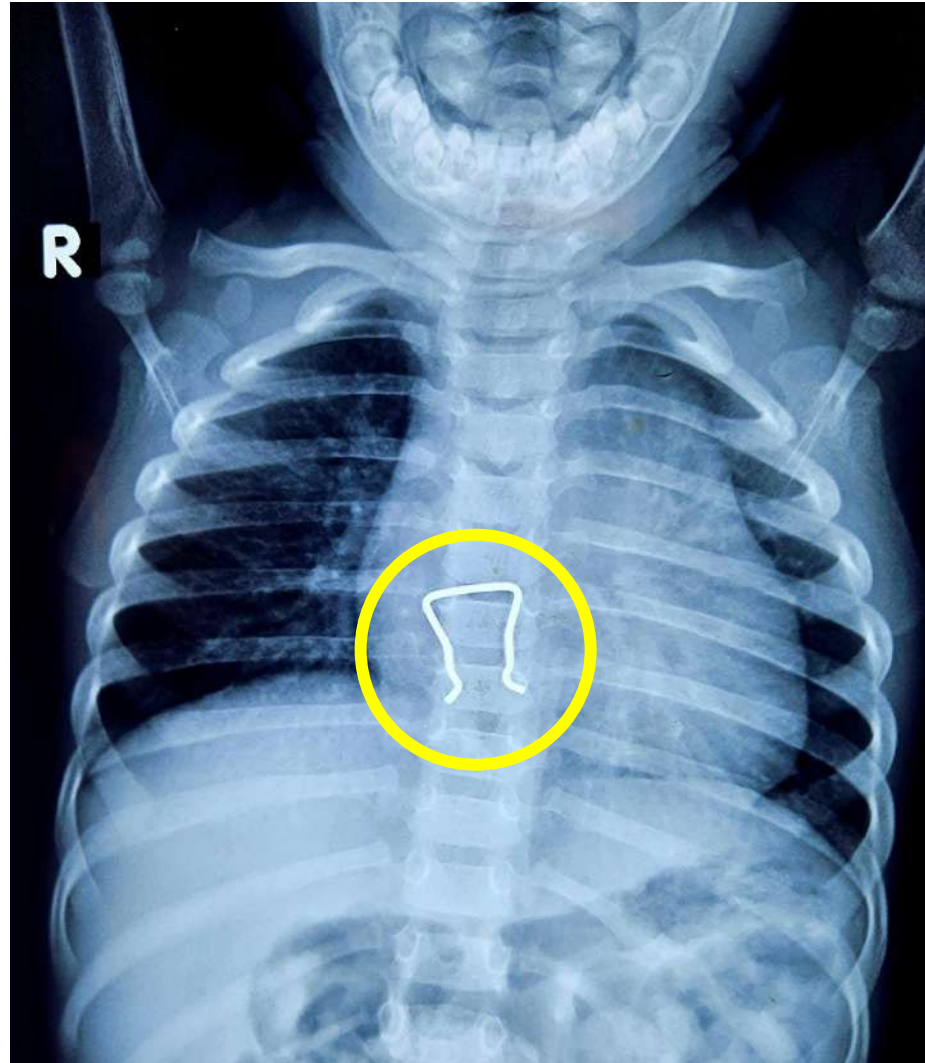
- ❑ A **1 years 4 months** old child, only **8.2 kg**, was presented with the complaints of:

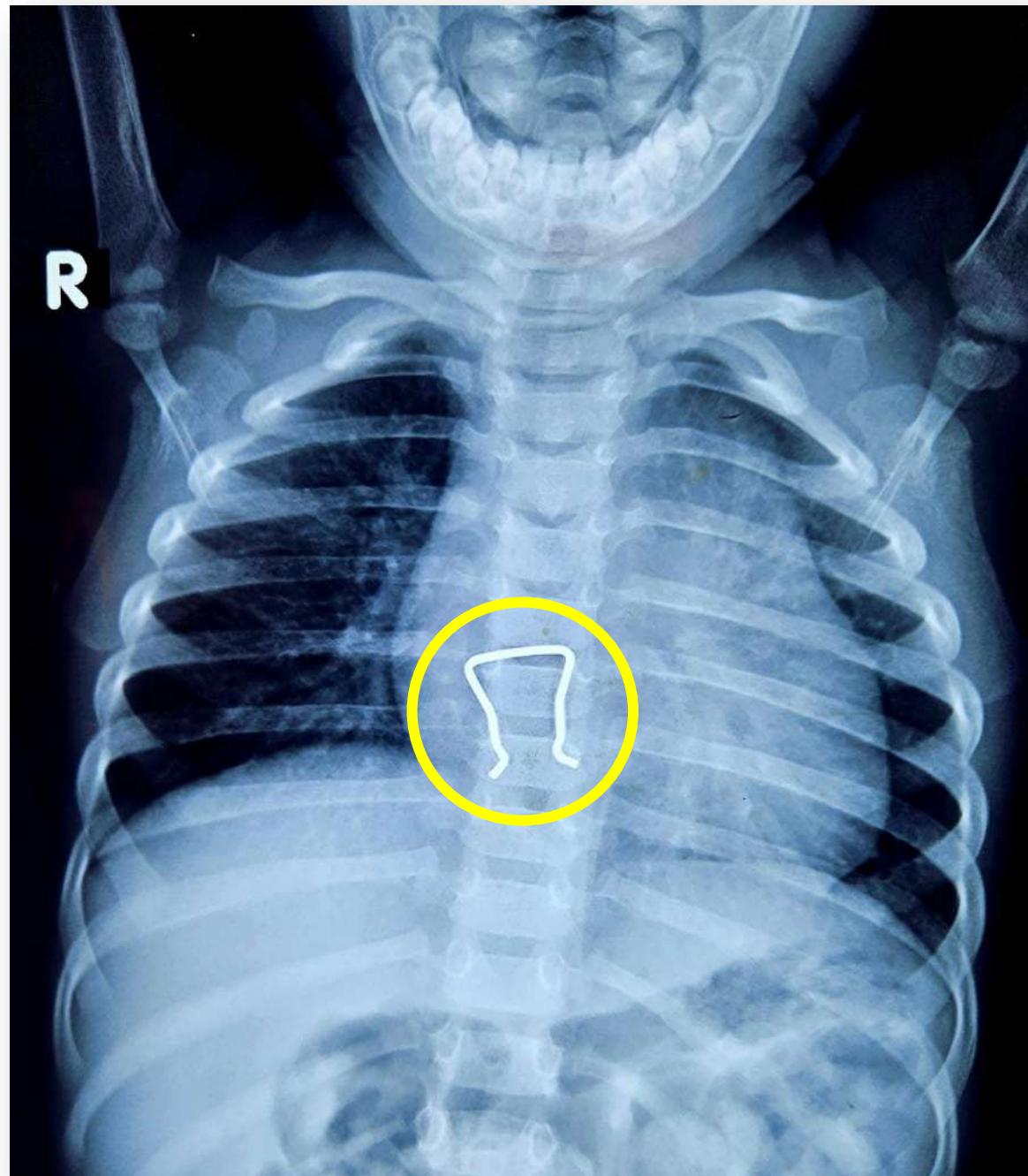


- ❑ Accidental ingestion of **Clothes clip spring** during playing time



# X-ray A/P View





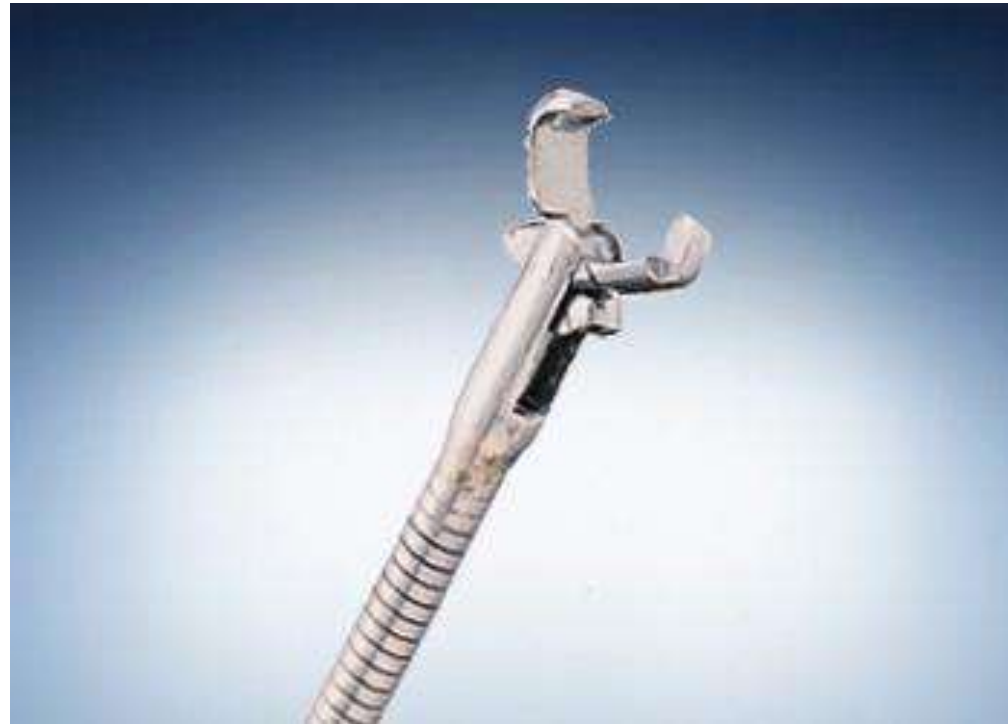# International Recommendation

❑ If foreign body having sharp end, then:

❑ Urgent removal of  
foreign body

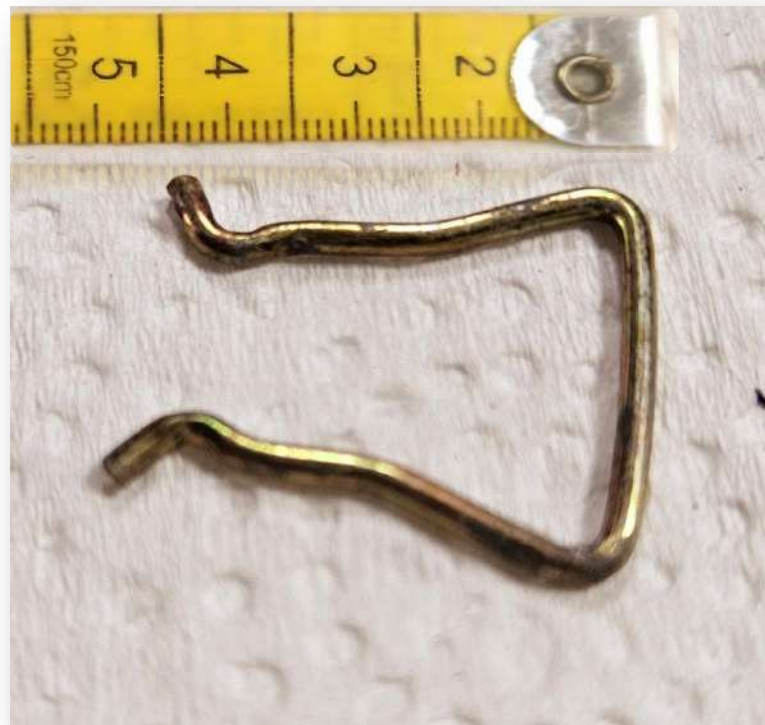# Instruments for Endoscopic removal

## Rat tooth forceps

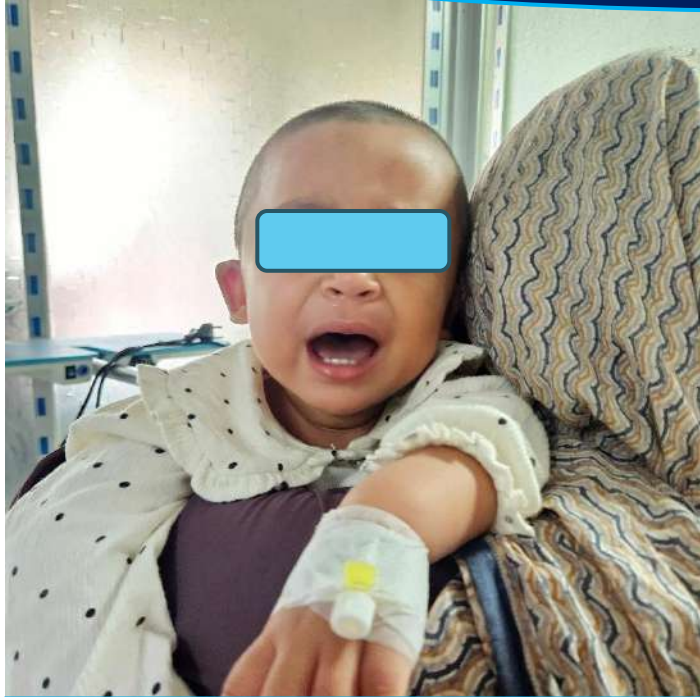



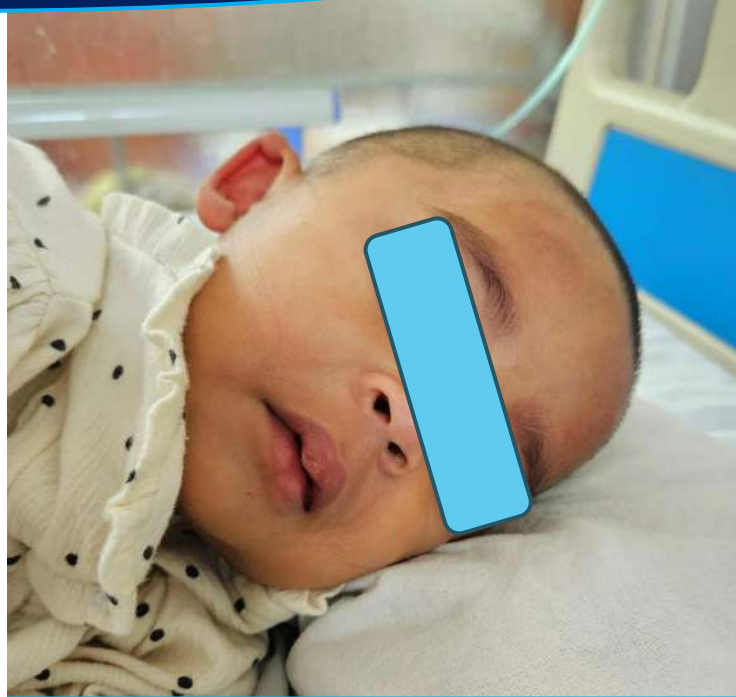# After Removal



# Clothes Clip Spring



**Before Removal**




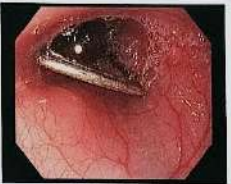
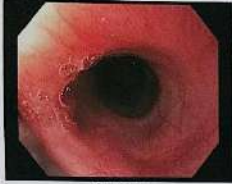
**After Removal**



# Endoscopy Report

BANGLADESH SHISHU HOSPITAL & INSTITUTE Sher-e-bangla Nagar, Dhaka-1207			
Identity No.	00001776	Visit Date	25 February, 2025
Patient Name	Manha	Age / Sex	1.4 / Female
History	Foreign Body Ingestion (clothes clip spring)	Instrument	N/A
Referrer	OPD	Bed	OPD

### ENDOSCOPIC PROCEDURE REPORT



Esophagus      FB in Esophagus      Gripping with rat tooth forceps

**Procedure :** UPPER G. I. TRACT ENDOSCOPY

**Indication :** Foreign Body Ingestion (clothes clip spring)

**Medication :** Inj. Midazolam 1/4 Slowly




**FINDINGS:**

- **Oesophagus:**  
The mucosa, vascular pattern, lumen and peristalsis appeared normal. Upper & Lower oesophageal sphincters are normal in position and function. There was a foreign body (clothes clip spring) lodged in the lower end of esophagus removed by rat tooth forceps.
- **Stomach:**  
The body, fundus & pylorus of the stomach appeared normal.
- **Duodenum:**  
The bulb, post-bulbar area appeared normal.

**COMMENTS:** Removal of foreign body (clothes clip spring) was done successfully.

**Prof. Dr. Salahuddin Mahmud**  
MBBS, MD (Pediatrics)  
Fellow training in Ped. Endoscopy  
Apollo Hospital, New Delhi (India)  
Sheffield Children Hospital (UK)  
Assistant Professor  
Pediatric Gastroenterology  
Hepatology & Nutrition

**Prof. Syed Shafi Ahmed**  
DCH, MD, FRCP, PhD  
Fellow training in Ped. Endoscopy  
Apollo Hospital, New Delhi (India)  
Sheffield Children Hospital (UK)  
Professor & Head  
Pediatric Gastroenterology,  
Hepatology & Nutrition



During removal      Stomach (Body)      After removal

Developed by: T. H. RYAD | www.bissoft.net | Distributed by: AL-FAYAT INTERNATIONAL | Phone: +880-2-9576101 | Fax: +880-2-9576881 | Email: info@al-fayat-bd.com

# Endoscopy Video



# Ped Gastro Team







Thanks

The word "Thanks" is written in a stylized, cursive font. The letters are primarily blue with a yellow-to-orange gradient. Two small, pink and black butterflies are perched on the letters: one on the 'T' and another on the 'Y'.

**Rely on us**

Thank You All &

