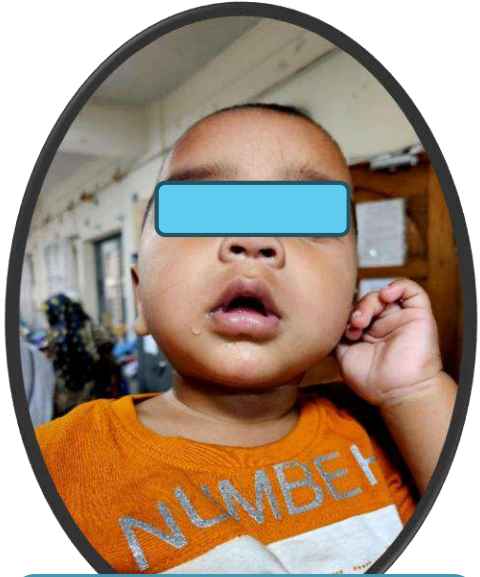

Endoscopic Removal of Brooch




Case scenario



Shehjad

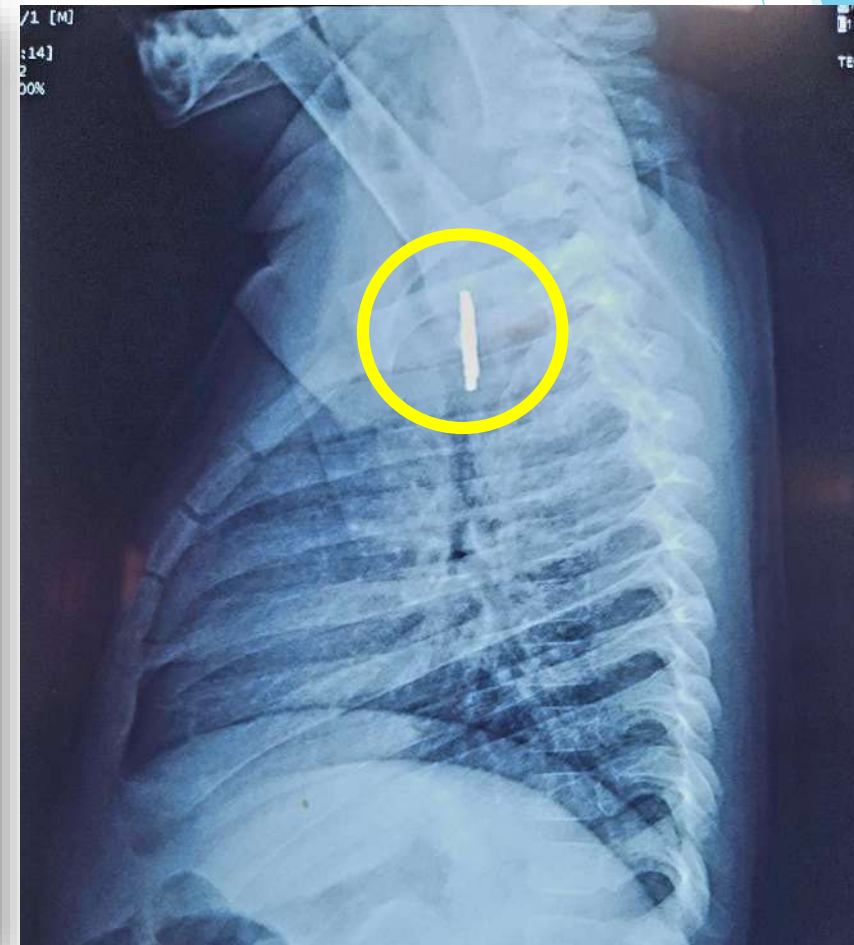
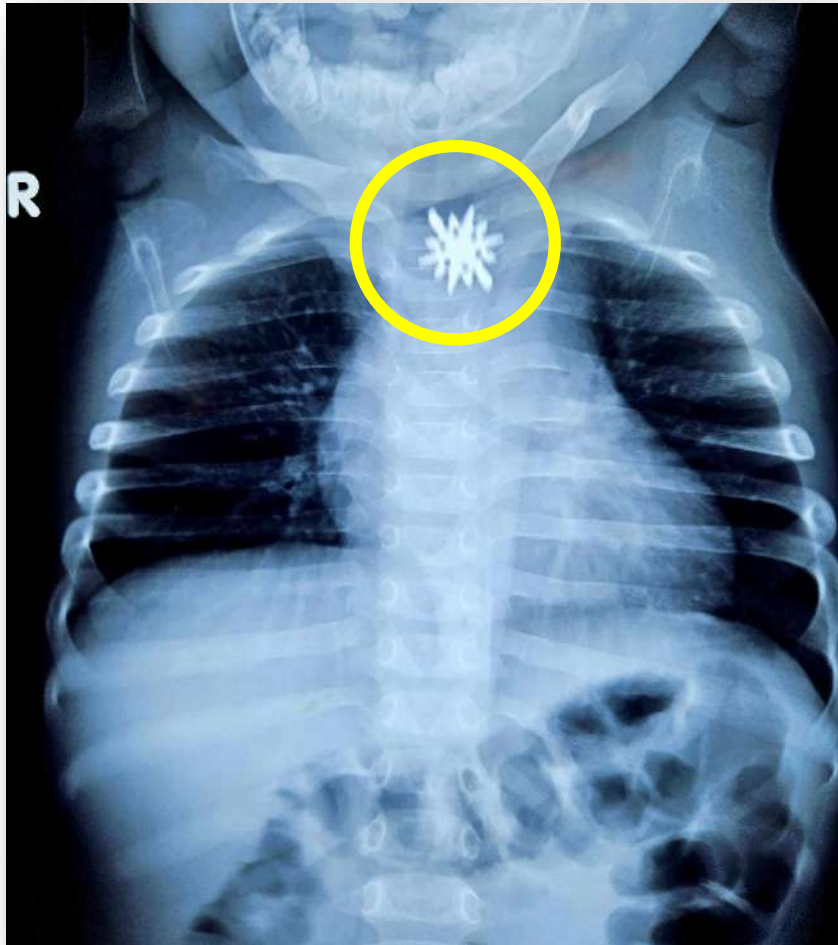


- ❑ A **1 years 4 months** old child, only **8.1 kg**, was presented with the complaints of:



- ❑ Accidental ingestion of **Brooch** during playing time

X-ray P/A & Lateral View



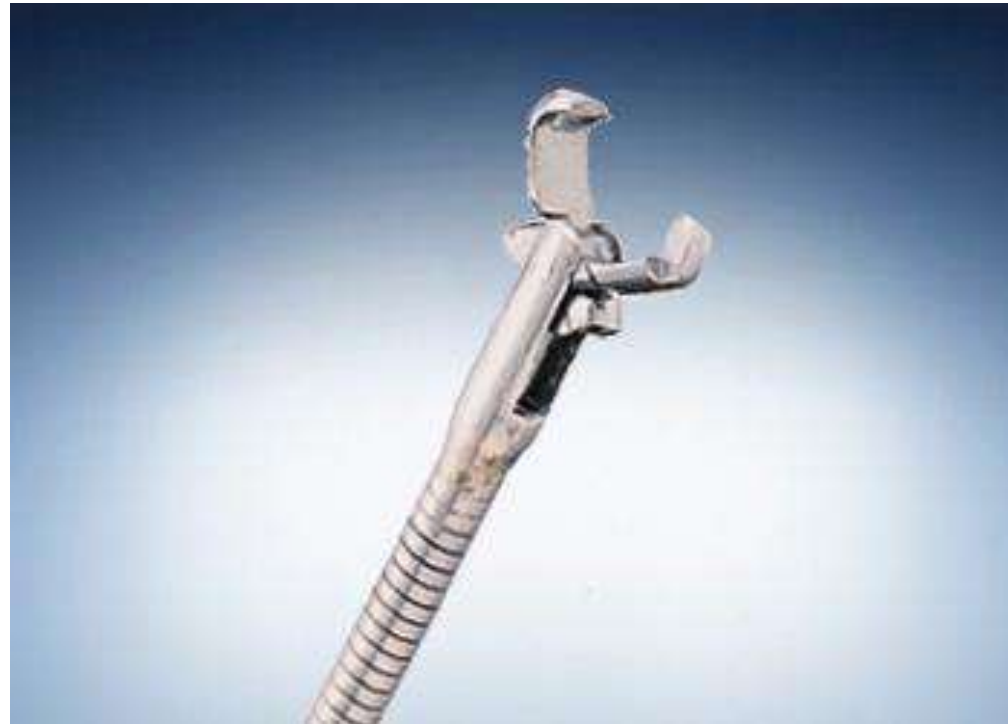International Recommendation

- ❑ If foreign body having **sharp end**,
then:

- ❑ **Urgent removal** of
foreign body

Instruments for Endoscopic removal

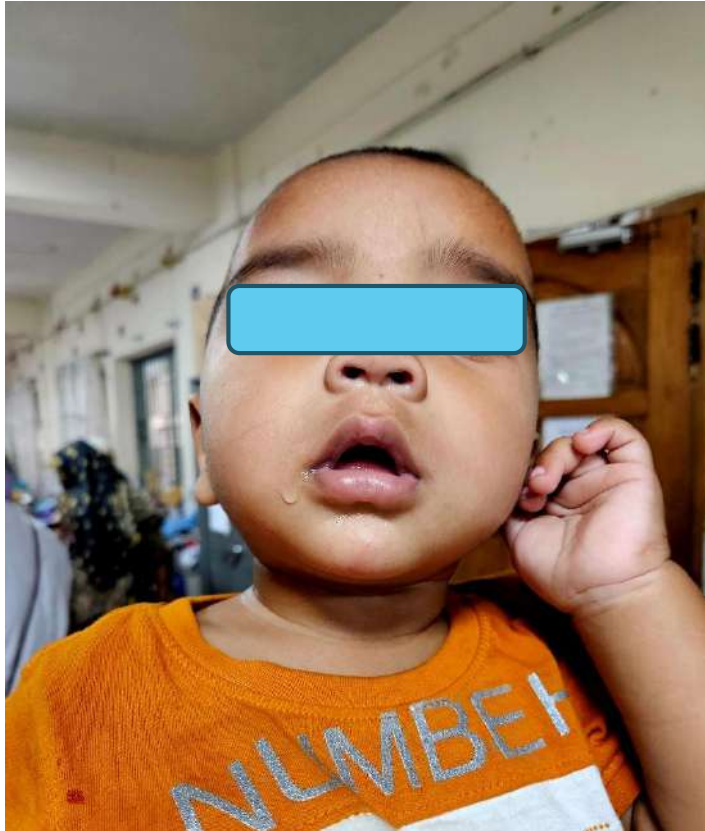Rat tooth forceps



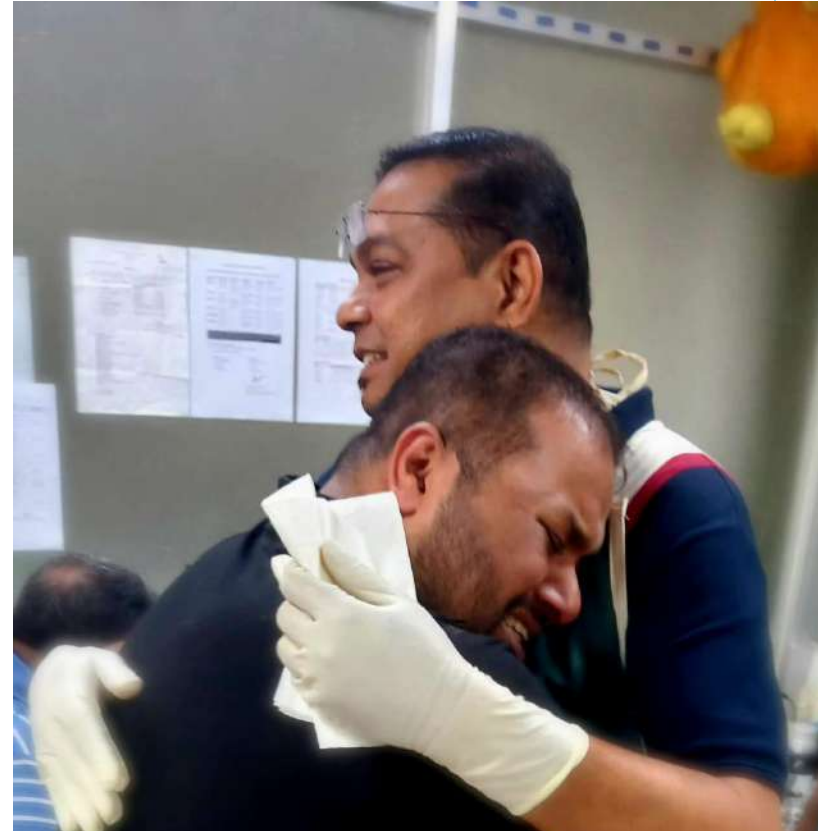After Removal



Brooch



Before Removal






After Removal

Endoscopy Report

BANGLADESH SHISHU HOSPITAL & INSTITUTE Sher-e-bangla Nagar, Dhaka-1207			
Identity No.	00001773	Visit Date	23 February, 2025
Patient Name	MD. Shehezad Sarkar	Age / Sex	1.4 / Male
History	Foreign Body Ingestion (Bronze)	Instrument	N/A
Referrer	Prof. Dr. Syed Shafi Ahmed	Bed	W-15, B-15

ENDOSCOPIC PROCEDURE REPORT



Esophagus (Upper end) Food Bolus Bronze in esophagus

Procedure : UPPER G. I. TRACT ENDOSCOPY

Indication : Foreign body ingestion (Bronze)

Medication : Inj. Midazolam IV Slowly




FINDINGS:

- **Oesophagus:**
The mucosa, vascular pattern, lumen and peristalsis appeared normal. Upper & Lower oesophageal sphincters are normal in position and function. There was a foreign body (Bronze) struck in middle of the esophagus. After removal ulceration was noted.
- **Stomach:**
The body, fundus & pylorus of the stomach appeared normal.
- **Duodenum:**
The bulb, post-bulbar area appeared normal.

COMMENTS: Endoscopic removal of foreign body (Bronze) was done successfully.

Prof. Dr. Salahuddin Mahmud
MBBS, MD (Pediatrics)
Fellow training in Ped. Endoscopy
Apollo Hospital, New Delhi (India)
Sheffield Children Hospital (UK)
Professor
Pediatric Gastroenterology
Hepatology & Nutrition

Prof. Dr. Syed Shafi Ahmed
DCH, MD, FRCP, PhD
Fellow training in Ped. Endoscopy
Apollo Hospital, New Delhi (India)
Sheffield Children Hospital (UK)
Professor & Head
Pediatric Gastroenterology,
Hepatology & Nutrition



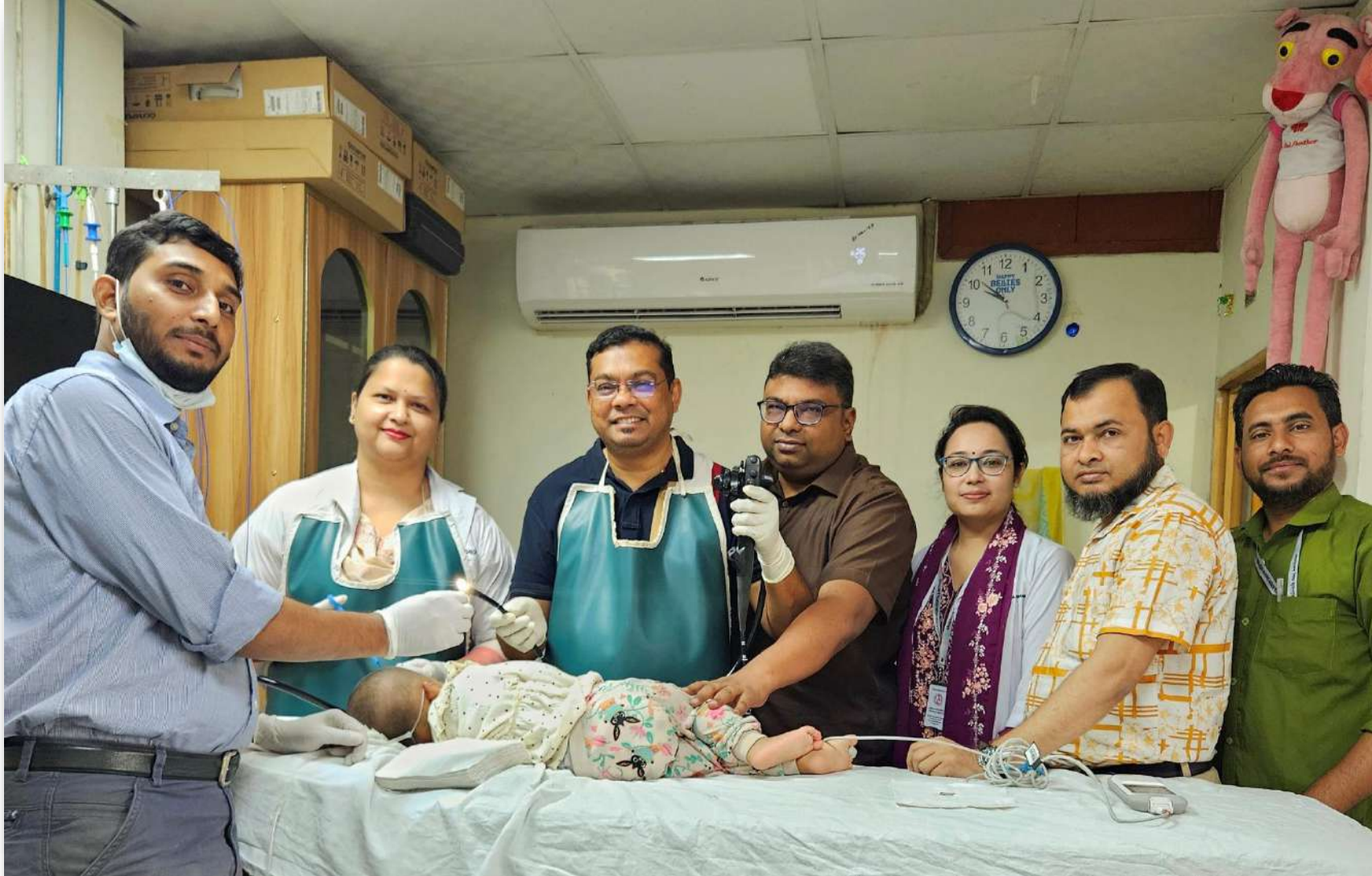Clear the food bolus During removal of foreign body After removal of foreign body

Developed by: T. H. RYAD | www.slipnet.net | Distributed by: AL FATAH INTERNATIONAL | Phone: +880-2-9678151 | Fax: +880-2-9678881 | Email: info@al-fatah-od.com

Endoscopy Video



Ped Gastro Team



**THANK
YOU ALL &**

