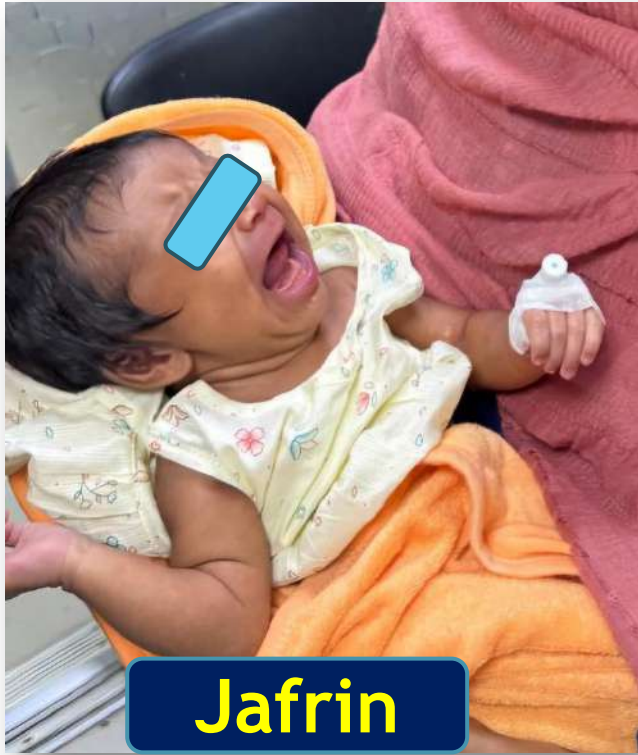

# Endoscopic Removal of Bag Runner



# Case scenario



**Jafrin**

❑ A **27 days** old neonate, only **3 kg**, was presented with the complaints of:

❑ Accidental ingestion of **bag runner** which was introduced by his own brother of 5 years

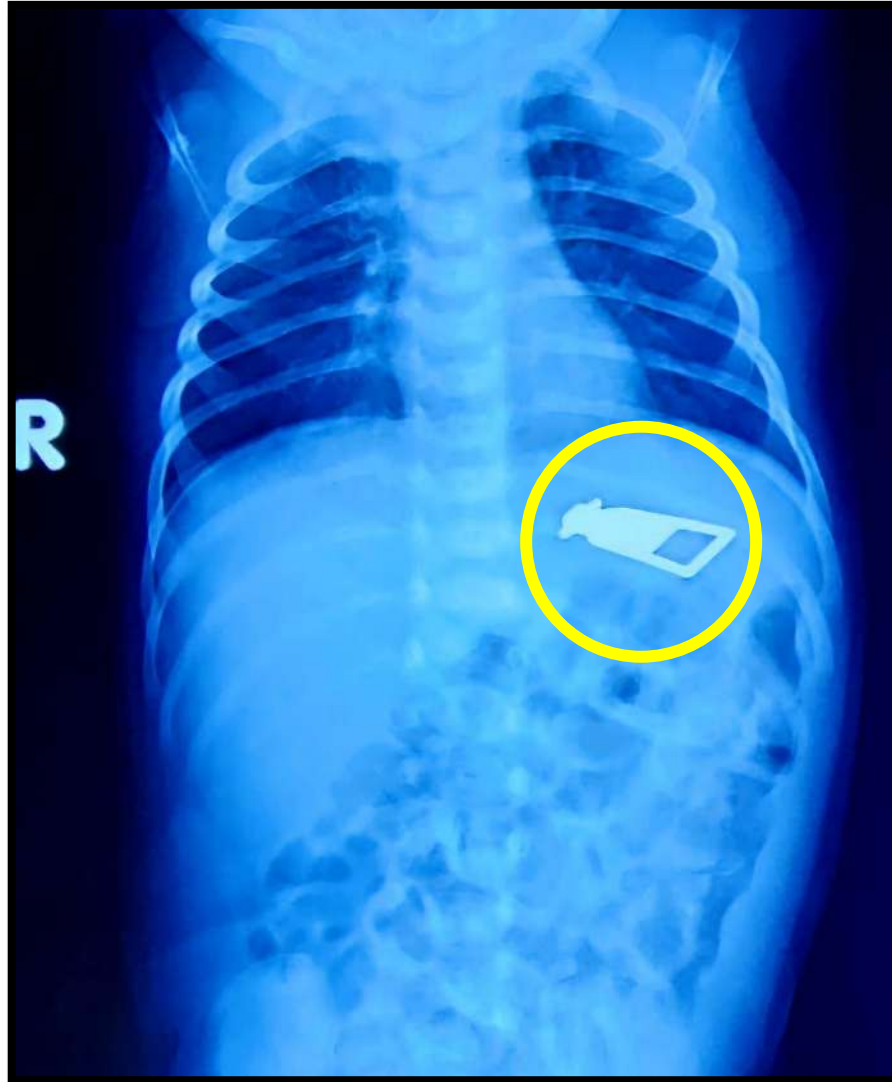


# Case scenario

After admission in chest hospital for 3 days, finally referred to **Bangladesh Shishu Hospital & Institute (BSHI)**

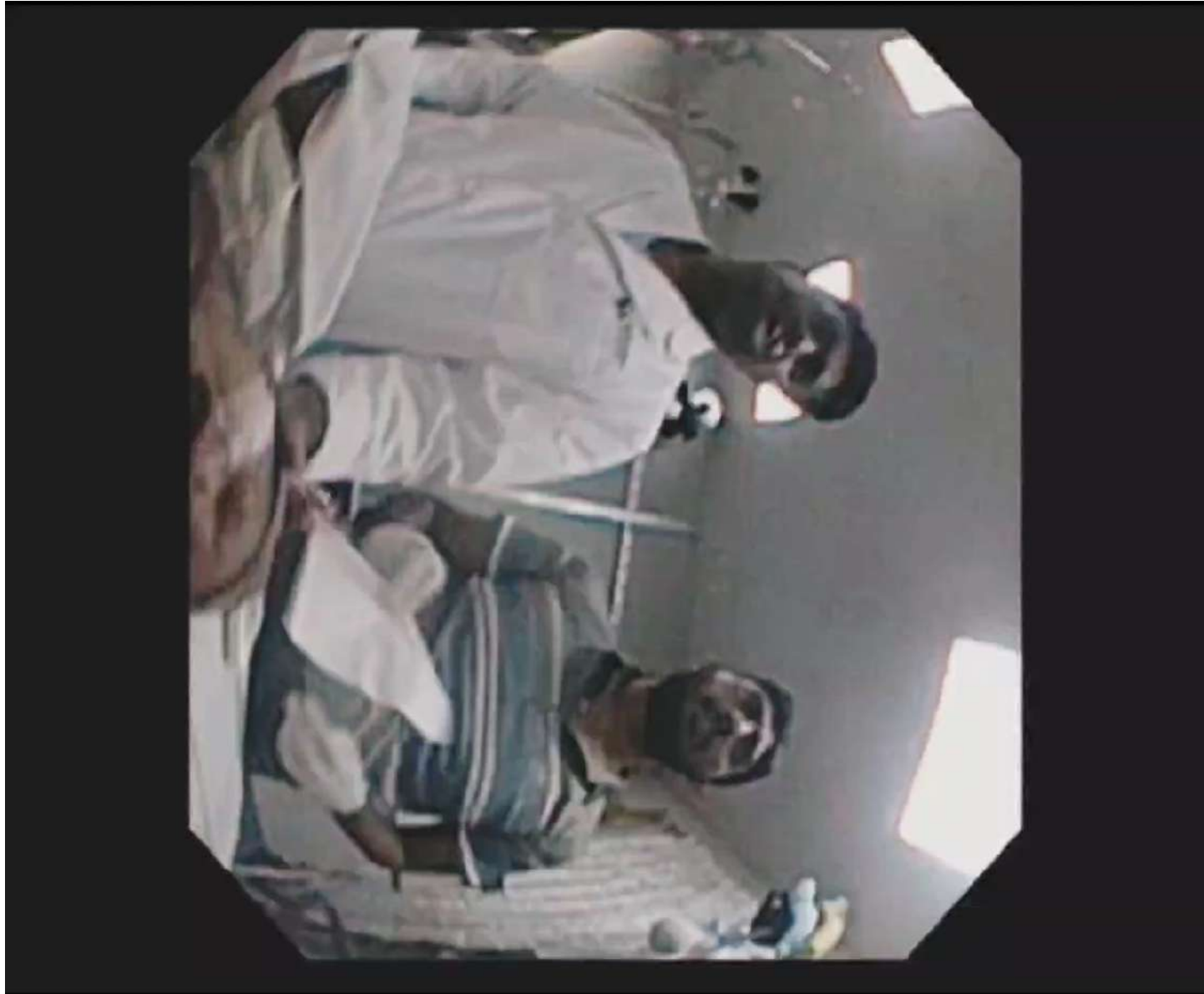

We performed **an X-ray** on an  
**emergency basis**











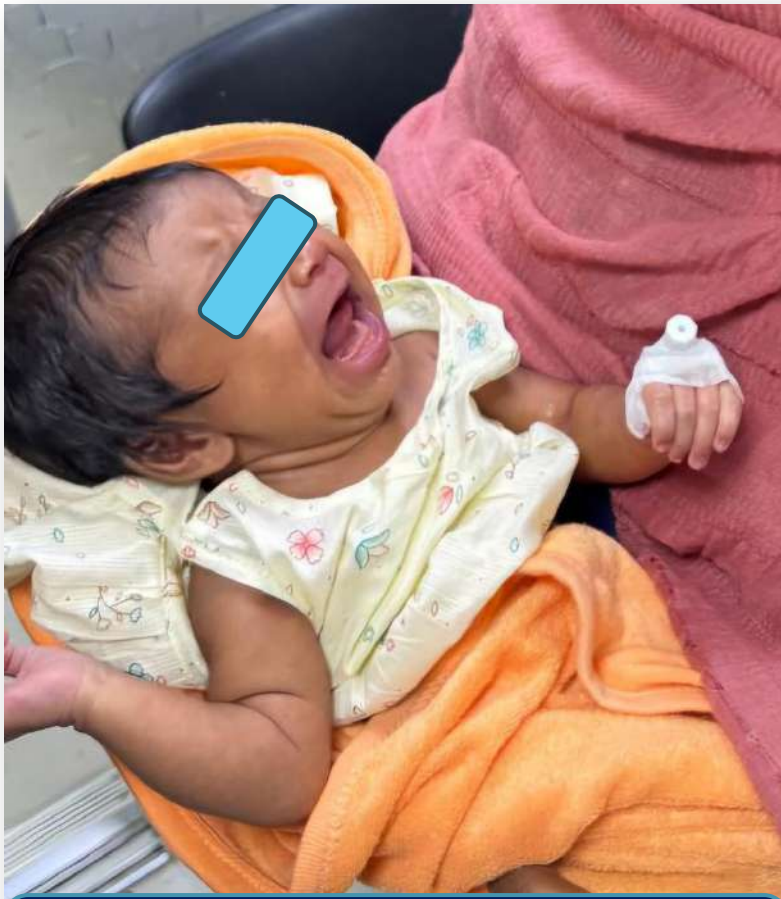

# Endoscopy Video

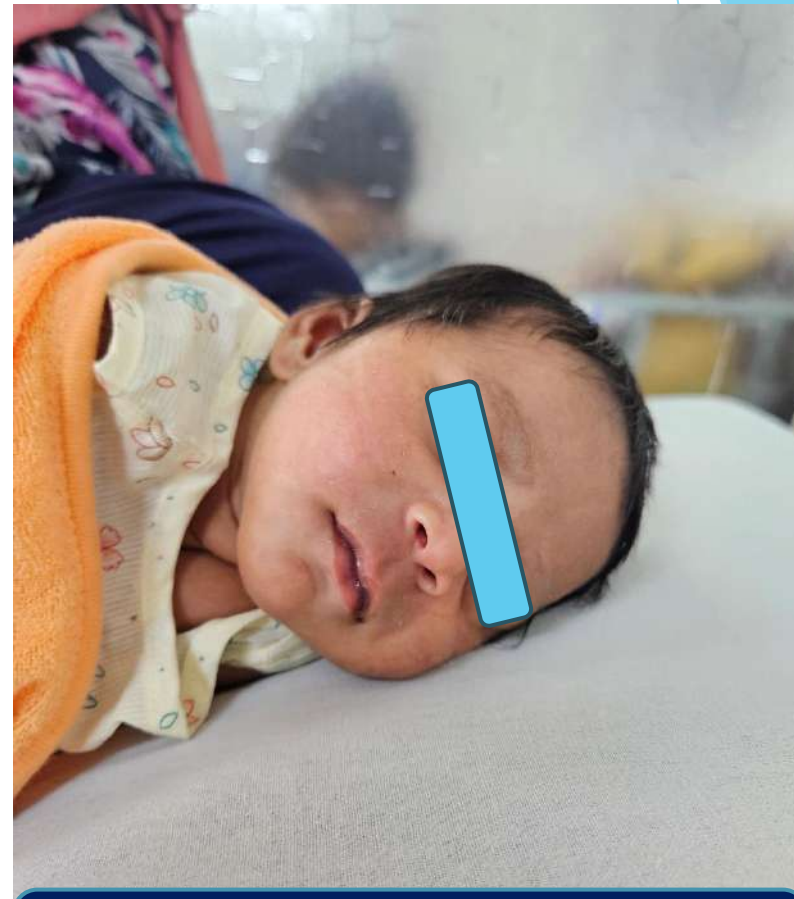

# Endoscopy Report

BANGLADESH SHISHU HOSPITAL & INSTITUTE Sher-e-bangla Nagar, Dhaka-1207			
Identity No.	00001814	Visit Date	22 March, 2025
Patient Name	Jafrin	Age / Sex	0.1 / Female
History	Foreign Body Ingestion	Instrument	Olympus CV-190
Referrer	OPD	Bed	OPD
ENDOSCOPIC PROCEDURE REPORT			
			
Esophagus (upper end)	Esophagus (lower end)	Foreign body in stomach	
<b>Procedure : UPPER GI Endoscopy</b>			
<b>Indication :</b> Foreign Body Ingestion			
<b>Medication :</b> Inj. Midazolam IV Slowly			
<b>FINDINGS:</b>			
<ul style="list-style-type: none"><li>• <b>Esophagus:</b> The mucosa, vascular pattern, lumen and peristalsis appeared normal. Upper &amp; Lower esophageal sphincters are normal in position and function.</li><li>• <b>Stomach:</b> A foreign body (metallic zipper runner) was found in body of the stomach. During procedure it was removed successfully by foreign body Roth net.</li><li>• <b>Duodenum:</b> Not seen.</li></ul>			
<b>COMMENTS:</b> Endoscopic removal of foreign body (metallic zipper runner).			
 <b>Prof. Dr. Salahuddin Mahmud</b> MBBS, MD (Pediatrics) Fellow training in Ped. Endoscopy Apollo Hospital, New Delhi (India) Sheffield Children Hospital (UK) Professor Pediatric Gastroenterology Hepatology & Nutrition		 <b>Prof. Dr. Syed Shafi Ahmed</b> DCH, MD, FRCP, PhD Fellow training in Ped. Endoscopy Apollo Hospital, New Delhi (India) Sheffield Children Hospital (UK) Professor & Head Pediatric Gastroenterology, Hepatology & Nutrition	
			
		Foreign body in stomach	
			
		During removal	
			
		After removal	
Developed by: T. H. RIYAD   www.bsssoft.net   Distributed by: AL-FATAH INTERNATIONAL   Phone: +880-2-9876101   Fax: +880-2-9876881   Email: info@al-fatah-bd.com			



**Before Endoscopy**



**After Endoscopy**

# After Removal of Bag Runner





# Ped Gastro Team

